

Complex Biopsy case study

Dale

Patient: Dale, 10-year-old, Male Neutered, Bulldog

Presenting complaint: Dale presented for a routine preventive care exam.

Physical examination: Dale had moderate pododermatitis and ceruminous debris AU. His spleen was subjectively enlarged. The balance of the physical exam was unremarkable.



Diagnostic plan

Samples were collected for an IDEXX CBC, serum chemistry including IDEXX SDMA, complete urinalysis, total T4, Fecal Dx®, and 4Dx® Plus Test.

There were some significant results of Dale's preventive care diagnostic tests:

- + CBC – revealed a mild, nonregenerative anemia and moderate lymphocytic leukocytosis
 - + RBC 4.79 M/uL
 - + Hematocrit 33.6%
 - + Hemoglobin 11.5 g/dL
 - + WBC 23.4 K/uL
 - + Lymphocytes 14.74 K/uL

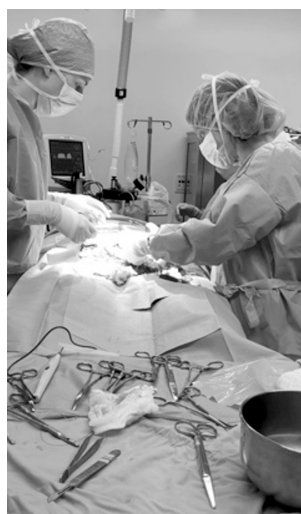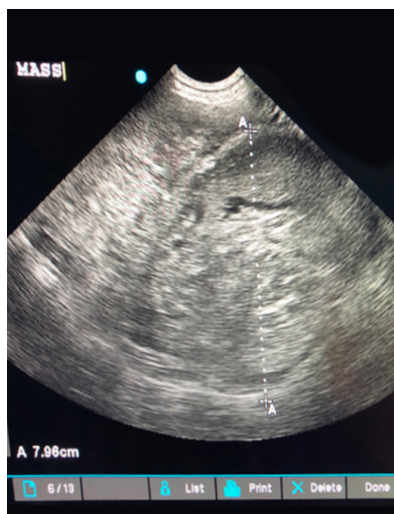- + Blood Chemistry Panel – revealed evidence of inflammation, but was largely unremarkable
 - + Mild hyperglobulinemia of 5.0 g/dL
 - + Mild hypoalbuminemia of 2.4 g/dL
 - + Otherwise, no significant findings
 - + SDMA 10 mg/dL (normal)
- + Lab 4Dx Plus negative
- + Fecal Dx negative
- + Total T4 1.7 ug/dL (1.0-4.0 ug/dL ref range)
- + Urinalysis – USG 1.028 with a quiet sediment

TEST	RESULT	REFERENCE VALUE	
RBC	4.79	5.39 - 8.70 M/μL	L
Hematocrit	33.6	38.3 - 56.5 %	L
Hemoglobin	11.5	13.4 - 20.7 g/dL	L
MCV	70	59 - 76 fL	
MCH	24.0	21.9 - 26.1 pg	
MCHC	34.2	32.6 - 39.2 g/dL	
% Reticulocyte	0.7	%	
Reticulocytes	34	10 - 110 K/ μ L	
Reticulocyte Hemoglobin	24.9	24.5 - 31.8 pg	
WBC	23.4	4.9 - 17.6 K/μL	H
Lymphocytes	14.742	1.06 - 4.95 K/μL	H

Total Protein	7.4	5.5 - 7.5 g/dL	
Albumin	2.4	2.7 - 3.9 g/dL	
Globulin	5.0	2.4 - 4.0 g/dL	
Albumin: Globulin Ratio	0.5	0.7 - 1.5	
ALT	19	18 - 121 U/L	
AST	15	16 - 55 U/L	
ALP	80	5 - 160 U/L	
GGT	1	0 - 13 U/L	

Abnormalities on the CBC were mild non-regenerative anemia and moderate lymphocytic leukocytosis.

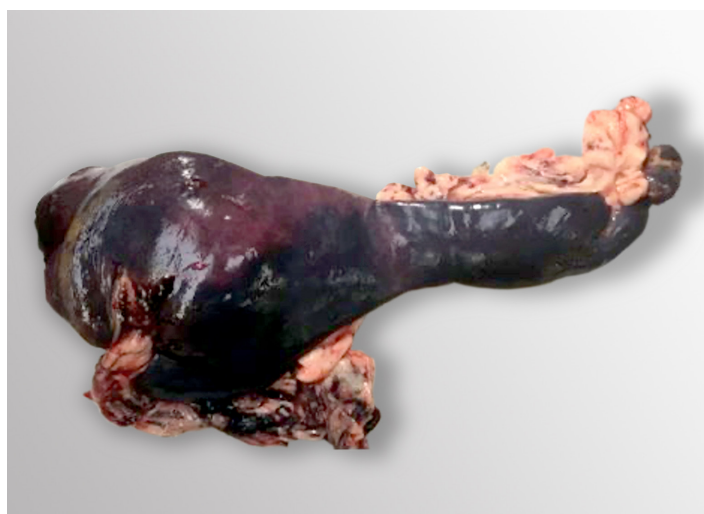The only other abnormalities of the balance of preventive care laboratory testing were hyperglobulinemia and hypoalbuminemia indicative of inflammation.



Abdominal ultrasound revealed a large (approximately 8 cm), heterogenous mass in the tail of the spleen. Thoracic radiographs were unremarkable (not shown).

Abdominal ultrasound was performed to further investigate Dale's possible splenomegaly; mild, nonregenerative anemia; and lymphocytic leukocytosis and revealed a splenic mass.

Dale had a splenectomy to enable histologic evaluation of his entire spleen which was submitted to IDEXX Pathology as a Complex Biopsy (7217). Upon receipt at the lab, the IDEXX histopathology technician performed a gross examination of the spleen and determined from which areas to obtain sample sections with the goal to obtain representative samples of the entire organ. In the image you can see that the different regions of the spleen have a varied appearance. This is why organs such as the spleen should be submitted whole using the Complex Biopsy test code.



Tail of the spleen with a mass. Head of the spleen appears grossly normal.

Histopathologic Diagnosis

Dale's pathology report returned the following result:

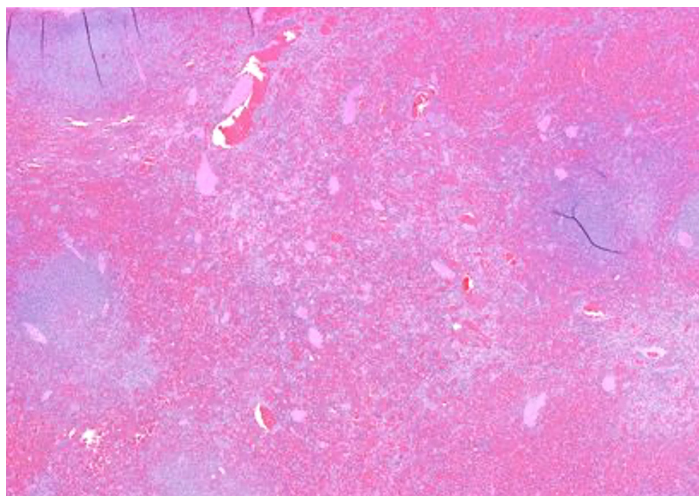
Splenic hematoma - The splenic parenchyma is compressed by an unencapsulated mass comprised of abundant erythrocytes admixed with numerous hemosiderophages and lesser numbers of lymphocytes, plasma cells, erythroid and myeloid precursors, and reactive spindle cells.

Atypical lymphoid proliferation - In the adjacent red and white pulp, there is an expanded population of intermediate sized, monomorphic lymphocytes that contain scant cytoplasm and irregularly oval nuclei containing stippled chromatin and a magenta nucleolus. The mitotic count is low (approximately 0-3 per single 400 X field).

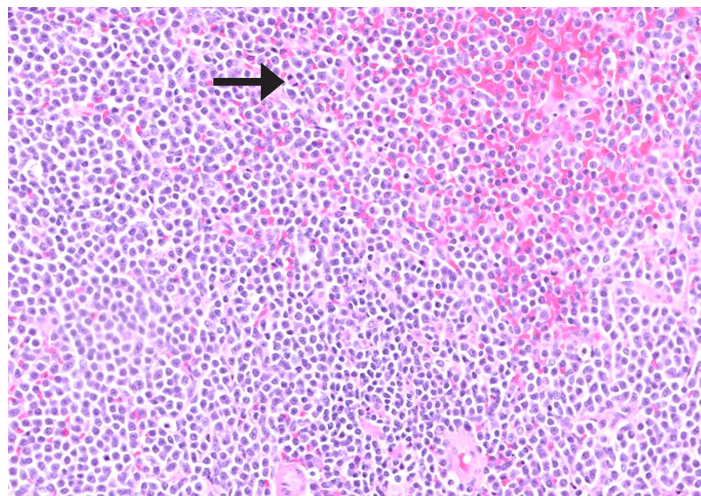
Dale's splenic mass was revealed to be a hematoma. The grossly normal-appearing region of Dale's spleen was indeed abnormal on histopathology. Here is where atypical lymphocyte proliferation, concerning for neoplasia, was discovered. This highlights the importance of submitting the whole organ with the Complex Biopsy test code.

Additional testing

Given the history and signalment of this patient, a novel condition of English Bulldogs, polyclonal B-cell lymphocytosis (PBLEB)¹ was considered. Polyclonal B-cell lymphocytosis is often associated with splenomegaly or splenic masses, and most cases have an indolent course similar to Dale.



Low magnification of the splenic mass. At the top of the image is the splenic capsule. You can see many erythrocytes which represent hemorrhage and pink areas which represent necrosis in this image. Necrosis and hemorrhage may overlay both benign and malignant splenic lesions so it is important to look elsewhere in the spleen to make a diagnosis of a benign or malignant lesion.



An area of white pulp (white pulp are purple areas of the spleen consisting of lymphoid tissue) at high power. The lymphocyte cells are intermediate sized with low mitosis (a single mitotic figure is indicated by the black arrow). The lymphocytes are monomorphic, have scant cytoplasm and irregularly oval nuclei with stippled chromatin and a single nucleolus. These findings, while abnormal, are not entirely suggestive of a cancerous process. Hence, further testing is needed.

Upon the advice of the pathologist, confirmatory testing was pursued which refuted a diagnosis of PBLEB. Flow cytometry of a whole blood sample from Dale revealed CD21 lymphocytosis (homogenous expansion of small B cells) and PARR (PCR for antigen receptor rearrangement) on whole blood indicated the presence of a clonally rearranged immunoglobulin gene. These results support a diagnosis of B cell chronic lymphocytic leukemia, a slow-to-progress disease that can originate in either the bone marrow or spleen.

Treatment and Outcome:

Dale’s owner elected to monitor without further treatment. Dale remains clinically well 9 months later at the time of this writing.

Summary:

Dale’s case highlights many important factors to consider with pathology submissions. IDEXX anatomic pathologists recommend submitting spleens in their entirety with the Complex Biopsy test code, rather than subsampling. For example, submission of a whole spleen is considered best medical practice and of higher diagnostic yield than submission of only portions or pieces of spleen. The pathologist may suggest ancillary tests necessary to gain the complete clinical picture, especially with complicated cases such as Dale’s. Ancillary tests such as PARR and flow cytometry are wondrous developments in pathology that enable much more complete understanding of clinical cases than previously possible.

The clinical signs and diagnosis of the case presented here are specific to this patient. Diagnostic and treatment decisions are the responsibility of the attending veterinarian.

References

1. Rout, ED, et al. Polyclonal B-cell lymphocytosis in English Bulldogs. J Vet Intern Med. 2020; 34:2622–2635.